Early And Late Outcome For Single Versus Double Stenting For Bifurcational Coronary Artery Lesions

Aram J. Mirza

Correspondence:
Dr. Aram J.Mirza
Interventional Cardiologist
Director, Cathlab,
Sulaimany Cardiac Hospital.
P.O. Box: 198, Sulsimany,
Iraq
Email: arammerza@ymail.com

ABSTRACT

Objectives: The purpose of this study is to evaluate two different techniques of stent placement in bifurcation lesions of coronary artery disease.

Background: Although stent placement with dedicated techniques has been suggested to be a useful therapeutic modality for treating bifurcation lesions, limited information is available if stent placement on the side branch and on the parent branch provides any advantage over a simpler strategy of stenting the parent vessel and balloon angioplasty of the side branch.

Methods: Between January 2010 and January 2012, we treated a total of 92 patients with bifurcation lesions with two strategies, stenting the parent vessel and balloon angioplasty of the side branch (group A, n=70) or stenting both vessels (group B, n=22). Angiograms were analyzed by quantitative angiography, and clinical follow-up was obtained for six months.

Results: Stent placement on both branches resulted in a lower residual stenosis in the side branch. Acute procedural success was similar in the two groups(100%).

At the six-months follow-up, the angiographic restenosis rate and the target lesion revascularization rate were similar in the two groups, but repeated percutaneous coronary intervention done for symptomatic patients with denovo lesions in other arteries. There was no difference in the incidence of six-months total MACE.

Conclusions: For the treatment of true bifurcation lesions, a complex strategy of stenting both vessels provided no advantage in terms of procedural success and late outcome versus a simpler strategy of stenting only the parent vessel.

Key words: Stent, Bifurcational, coronary arteries.

Discussion

Among complex coronary lesions, bifurcations are those most frequently encountered by every interventional cardiologist. Bifurcation complexity essentially relies on their specific anatomic configuration, which is imperfectly handled by current coronary devices.

Anatomy of Bifurcation Lesions

A coronary bifurcation is a branching artery constituted by a main vessel (MV) and a side branch (SB). The segment before the origin of the SB is referred to as proximal MV, whereas the one that is distal to it is referred to as distal MV. The tissue membrane separating the origins of the 2 bifurcation arms is called the flow divider or carina.

Operative definitions of bifurcation lesions have been based on the SB diameter, either arbitrarily or in relation to potential blood supply.

Actually, a bifurcation stenosis is defined as a coronary artery narrowing occurring adjacent to and/or involving the origin of a significant SB (3). To be significant the SB has to be considered important in the individual patient according to symptoms, location of ischemia, vitality, collateral vessels, and left ventricular function.

Morphology classification is mainly based on plaque distribution. Indeed, plaque distribution can variably involve the proximal MV, the distal MV, or the SB. This has engendered at least 6 different classification schemes (1,3).

Sometimes, branching arteries are called "true" rather than "false" bifurcations according to the mere presence or absence of significant SB stenosis.

Pathological examination (4,5) of coronary arteries reveals that the atherosclerotic plaques are mainly located in areas of low shear stress, such as the lateral walls of the MV and SB, whereas they are less common at the carina level, which is characterized by high shear stress.

The spatial relation between the 2 arms of the bifurcation can be defined by 3 angles that have been recently named A (the angle between the proximal MV and the SB), B (the angle between the SB and the distal MV), and C (the angle between the proximal and distal segment of the MV). At times, bifurcations are defined as V- or T-type according to angle B being < 70° or > 70°, respectively.

Moreover, the proximal and distal branches of a bifurcation often do not lie on a single plane, thus posing significant challenges to quantitative coronary angiography software.

A recent ex vivo study of polymer casts of human coronary arteries has revealed a complex curvilinear transition zone between MV and SB, mainly characterized by an elliptical and asymmetrical configuration of the SB ostium and brief tapering of the SB origin (2,3).

Moreover, it has been previously pointed out that SB ostium asymmetry increases with increasing bifurcation angles. In bifurcations, there is also an asymmetrical geometric reduction according to the law of conservation of energy (2,3).

The complex interaction among different factors makes every bifurcation lesion quite unique, although certain lesion characteristics have been associated with treatment success when using currently accepted techniques and DES platforms (5,6)

The treatment of stenoses at a bifurcation remains one of the most challenging lesion subsets in coronary angioplasty.

Bifurcation lesions carry a risk of side branch occlusion because of plaque redistribution or so-called "plaque shift" across the carina of the bifurcation. The risk is increased if there is an eccentric lesion at the bifurcation site and a stenosis in the ostium of the side branch (7,8,9).

To lower the risk of plaque shift, the "kissing" balloon technique was developed (2). However, the results after balloon dilatation of bifurcation lesions are frequently suboptimal with a high incidence of complications and restenosis(7,8,9). It has also been pointed out that optimal results and low complication rates could not necessarily be anticipated by all operators (8).

The use of coronary stents has improved the treatment of bifurcation lesions, but they are technically challenging and there is compromising of the branch vessel (10,11,12).

Stent implantation on both the parent vessel and the side branch, which is called "kissing stents," is a useful technique for maintaining maximum expansion of both vessels(12,13).

The use of two stents minimizes lumen loss of one side during expansion of the other vessel (12).

The six main techniques used for bifurcation stenting (the "T" stent and modified "T" stenting, the "V" stent, the 'Y" stent, crush technique and the "Culotte" technique) have been shown by figures 1, 2, 3, 4, 5 and 6 (13,14).

Although these dedicated techniques have evolved along with new stent designs, it is not clear if the strategy of stenting both vessels provides better outcome than that of stenting only the parent vessel. So far, only case reports or limited series are available to understand the results of these different techniques(10,11,12,13,14,15).

For this reason, we analyzed in-hospital results and long-term outcomes for 92 consecutive patients with true bifurcation lesions treated with either stenting both vessels or stenting the

parent vessel plus balloon angioplasty for the branch and we use Madina classification in our description and management of bifurcational lesions(fig .8)

Until the advent of drug-eluting stents (DES) and dedicated techniques, percutaneous bifurcation interventions were associated with very high rates of unfavorable outcomes (12,13,14). Nevertheless, procedures directed to bifurcation treatment are often technically demanding and require proper execution. When implementing dedicated percutaneous bifurcation approaches, kissing balloon (KB) has been variably recommended to optimize stent apposition, correct stent deformation or distortion and improve side branch (SB) access. Over the years, KB has been deeply investigated by many different methods, from bench testing and computer simulations to in vivo intravascular imaging and clinical studies that have produced a large amount of data.

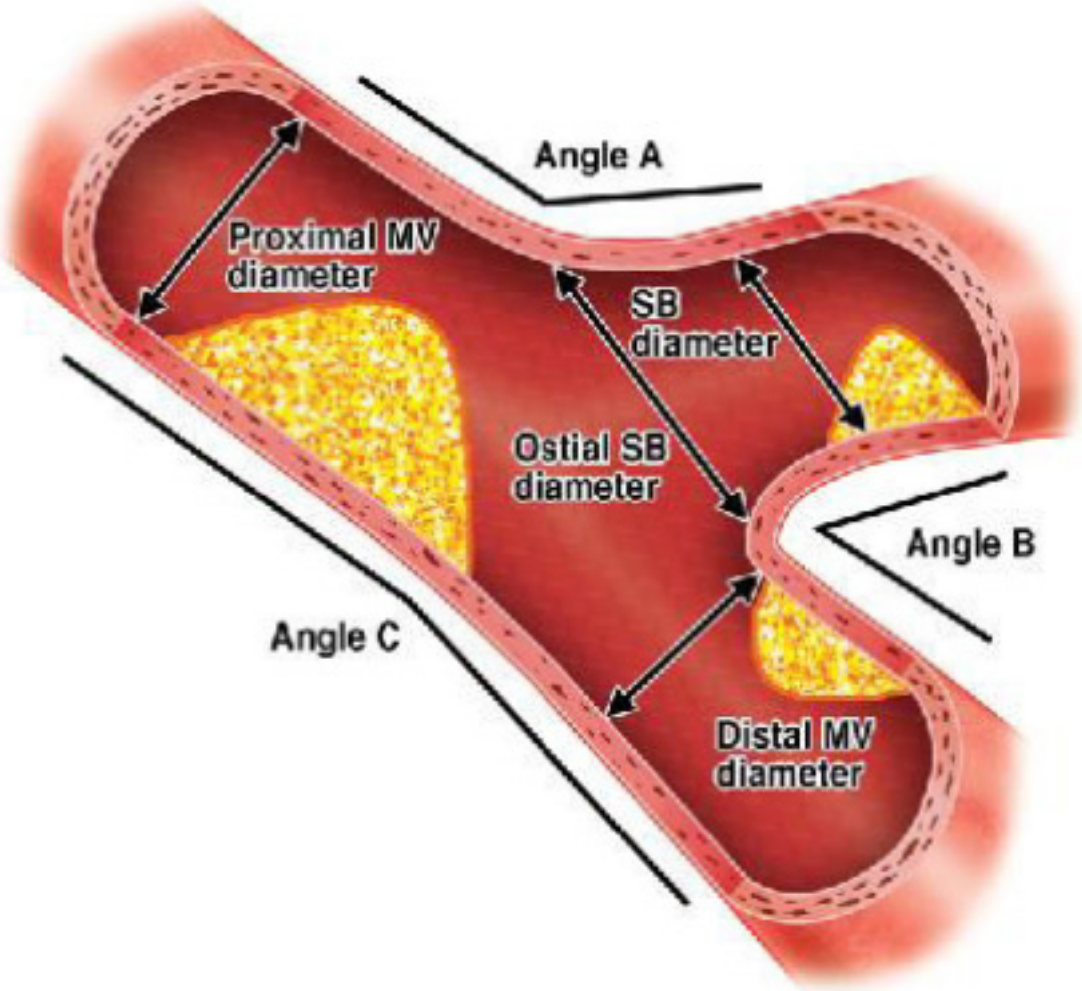

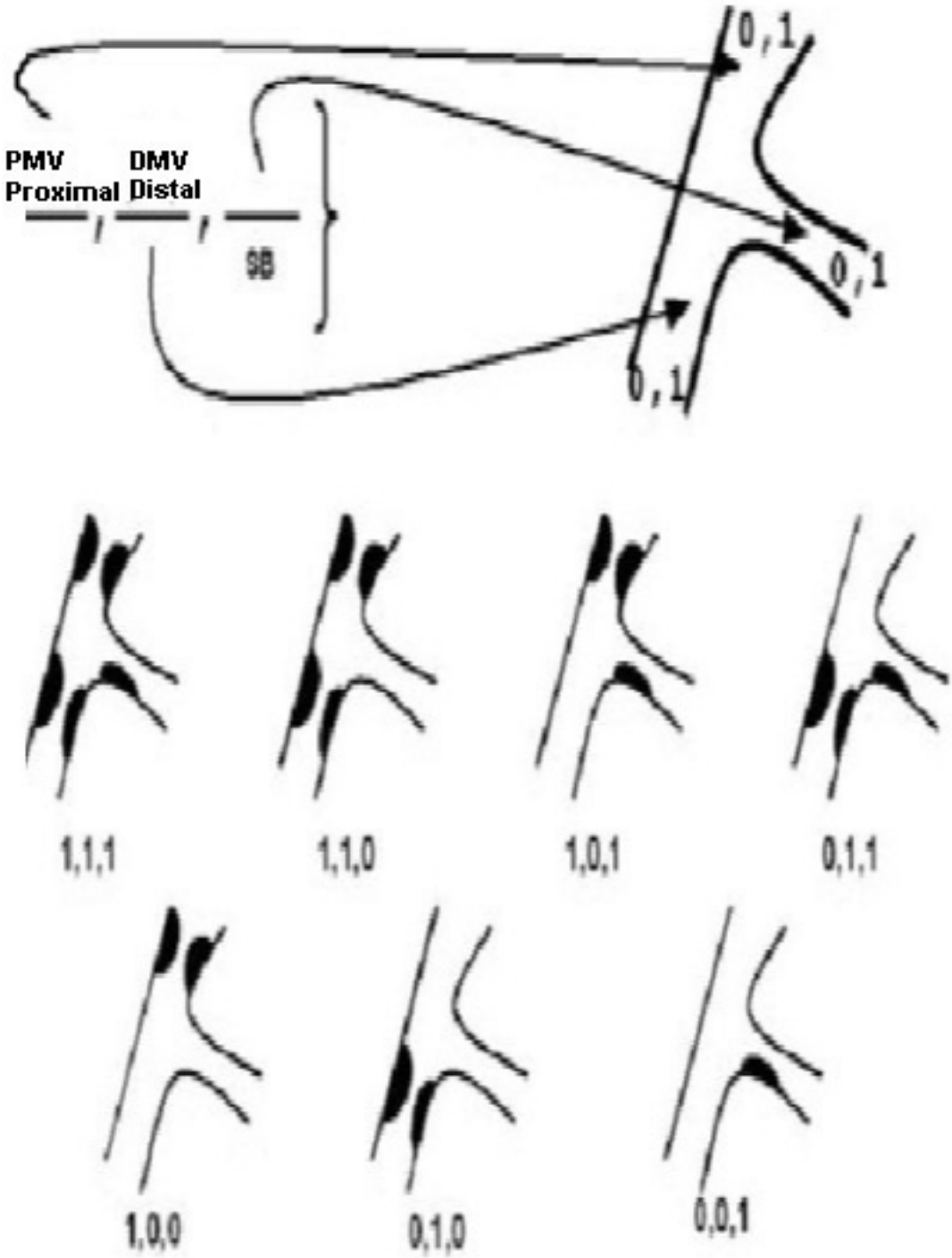
PMV
Proximal
DMV
Distal
SB
0 , 1
0 , 1
0 , 1
1,1,1
1,1,0
1,0,1
0,1,1
1,0,0
0,1,0
0,0,1

Figure 1:

The "V" and "simultaneous kissing stents" (SKS) stenting technique.

FK - final kissing; MB - main branch

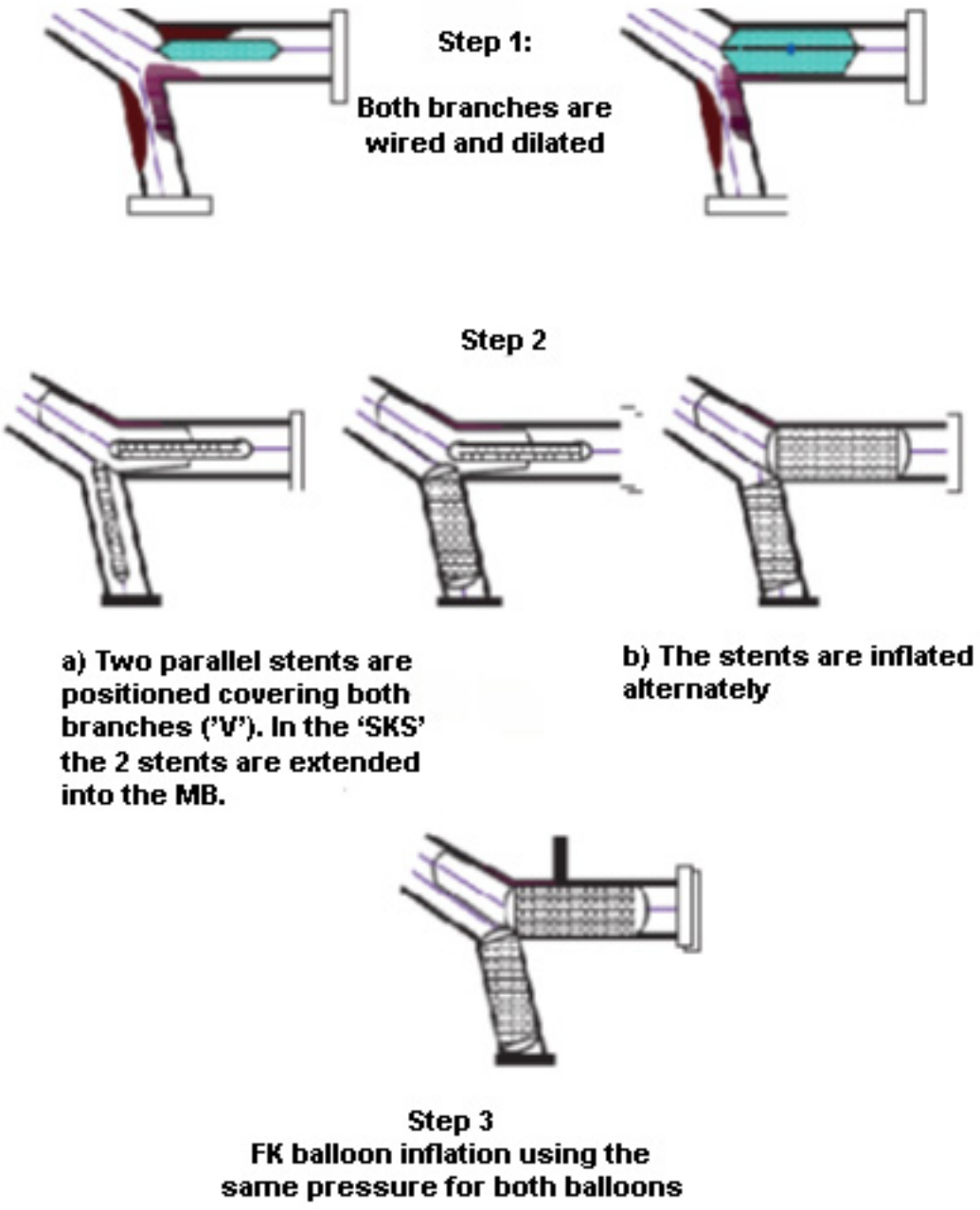

Figure 2:

"Crush" technique.

FK - final kissing;
MB - main branch;
SB - side branch.

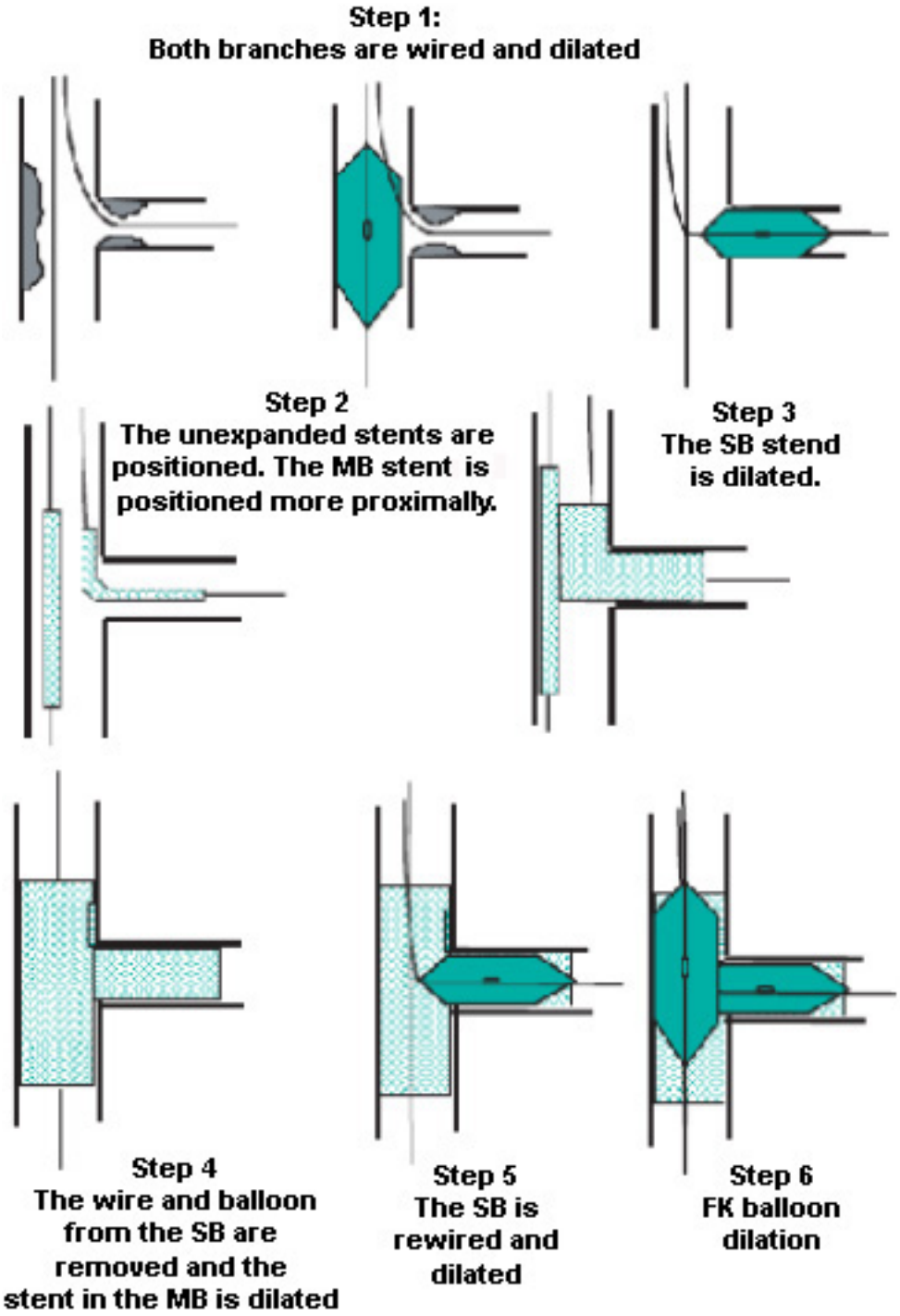

Figure 3:

The T stenting technique (through the stent).

FK - final kissing;
MB - main branch;
SB - side branch

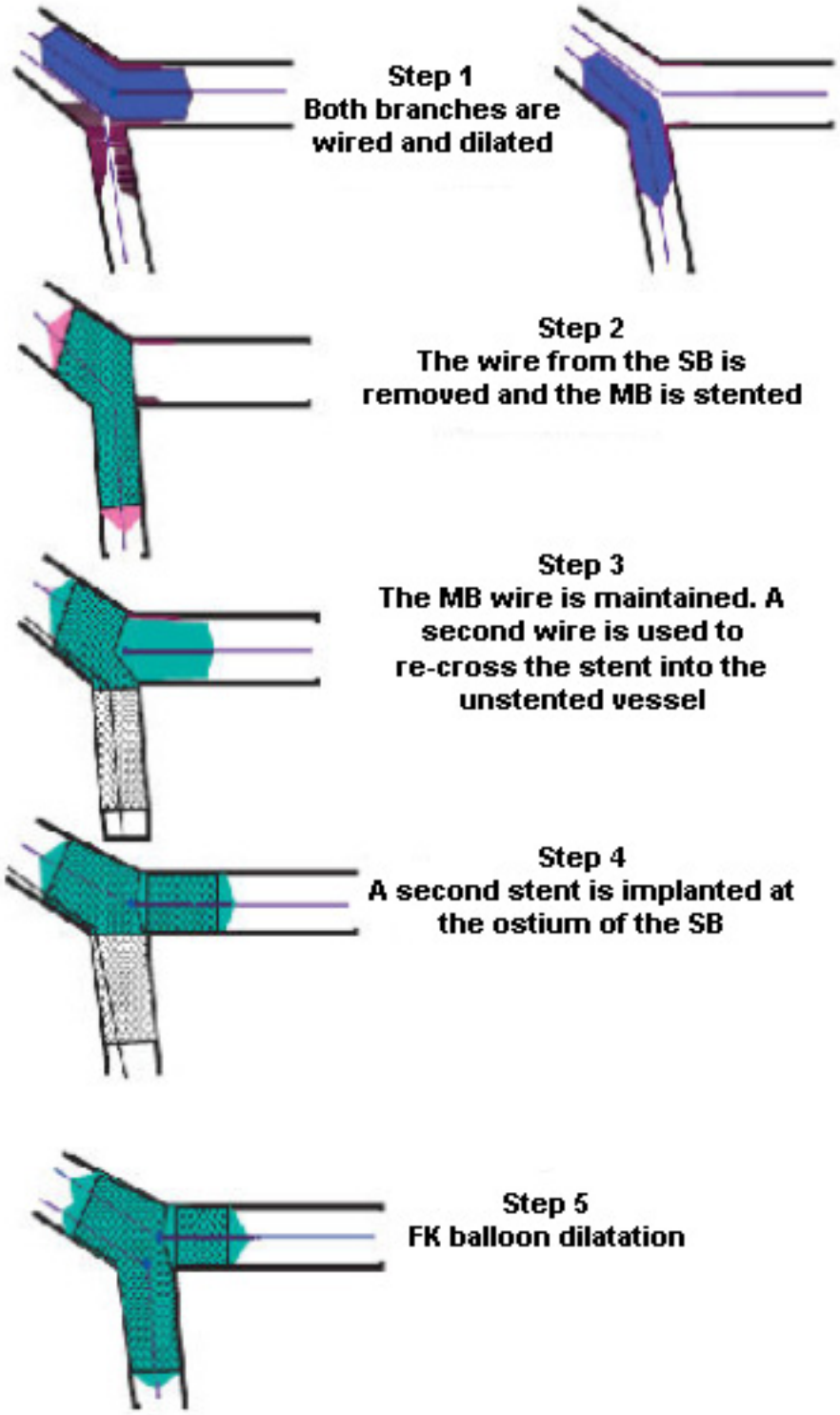

Figure 4:

The modified "T" stenting technique.

FK - final kissing;
MB - main branch;
SB - side branch

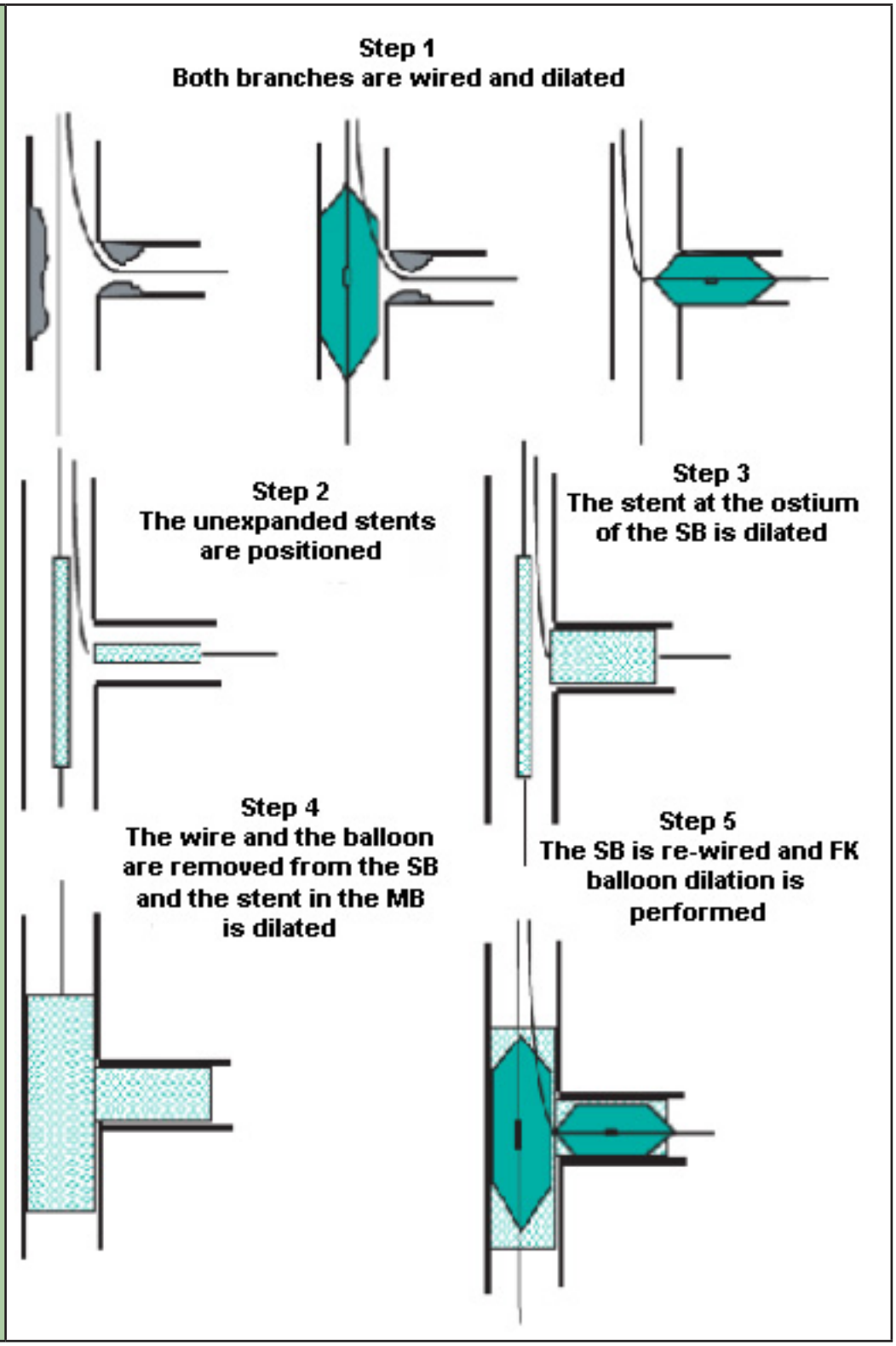

Figure 5:

The "cullottes" stenting technique.

FK - final kissing

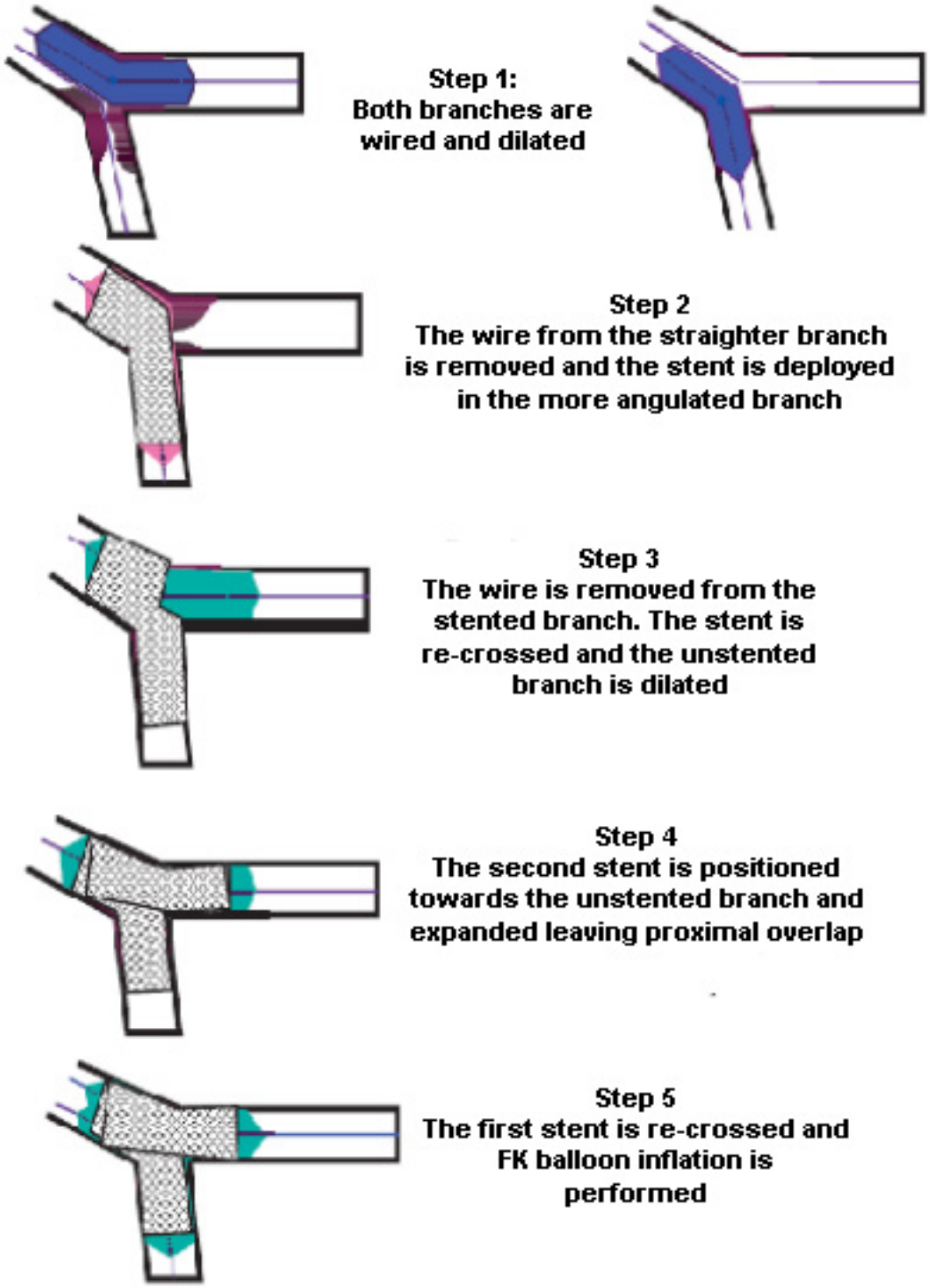

Figure 6: The "Y" stenting technique. FK - final kissing

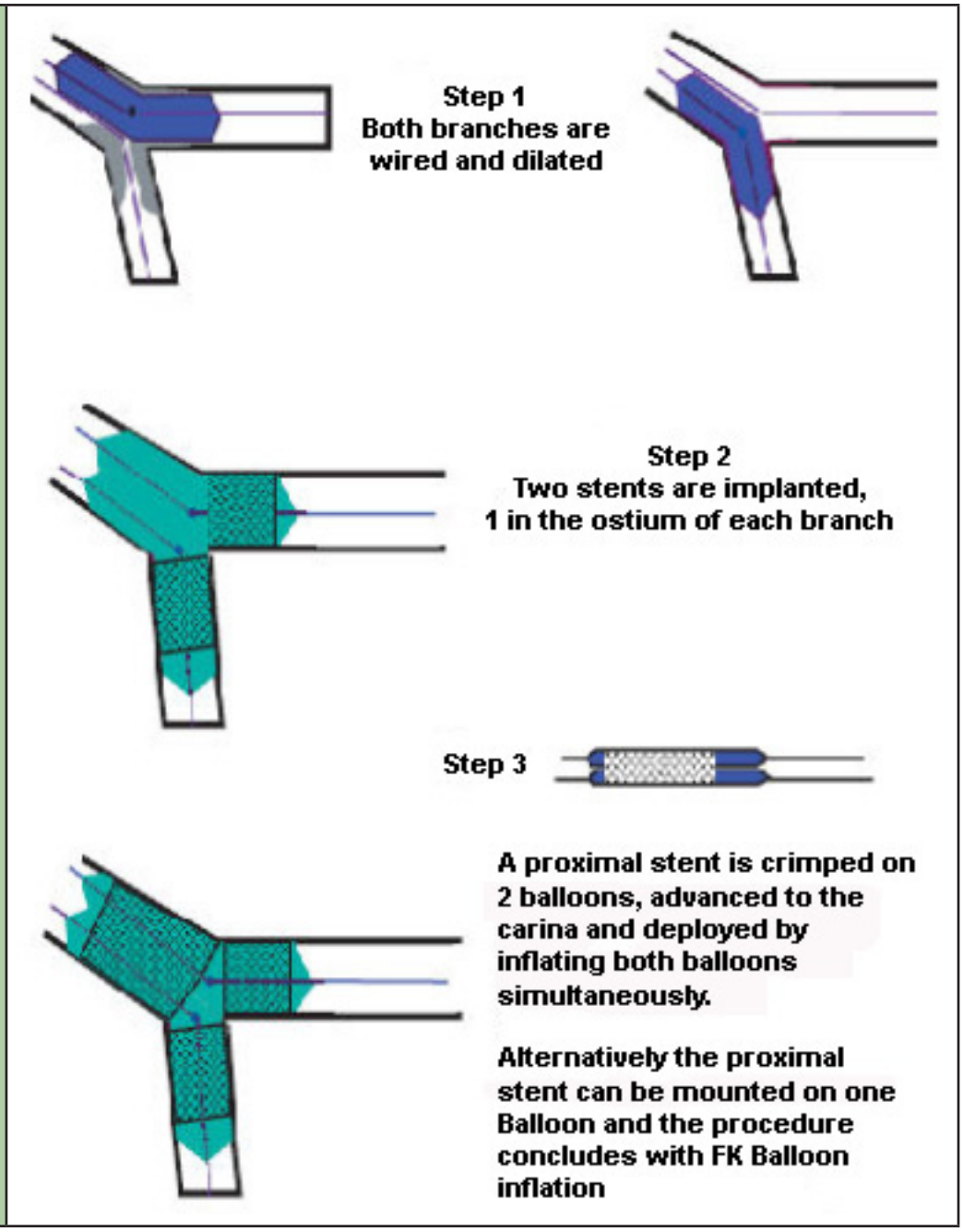

Methods

Study Population

The study was done retrospectively and prospectively between January 2010 and January 2012. A total of 92 patients underwent coronary stenting at Sulimaniya Center For Heart Disease for the treatment of symptomatic bifurcation lesions that had a >50% diameter stenosis in both the parent vessel and the ostium of the contiguous side branch and the lesions confirmed by two interventional cardiologists.

Informed consent for coronary angiography and stent implantation was obtained from all patients.

Revascularization Procedure and Stenting Strategies

Before angioplasty, the patient was on maintenance dose of oral aspirin with clopidogrel loading dose (600mg) given a day before the intervention and intravenous bolus of heparin (70-100Unit/kg) were administered to all patients at time of intervention.

Angiograms in multiple views were obtained using the transfemoral approach.

After placement of the guiding catheter, two wires were inserted in the distal bed of the two branches.

Balloon angioplasty was conducted by sequential inflation of a semicompliant balloon in each branch.

Two strategies for bifurcations were available

A less complicated angioplasty strategy that used stenting in only the parent vessel of the bifurcation lesions (group A) and a more complicated angioplasty treatment strategy that included stenting of both branches of bifurcation lesion (group B) was undertaken.

As a general rule, both lesions were stented when the reference vessel size of the side branch was greater than 2.0 mm. Group A was comprised of 70 patients and Group B was comprised of 22 patients.

For group A, the stent was implanted in the parent vessel and then balloon dilatation was performed through the stent struts into the side branch. Simultaneous kissing balloon inflation was frequently performed on completion of the procedure. For group B, stent placement for both vessels was performed using one of the previously reported techniques (Figures1,2,3,4,5,&6).

Angiographic Analysis and Clinical Follow-up

We used a computer-based QCA-CMS system version 4.0 for quantitative coronary angiography (QCA), with the dye-filled catheter as a reference. Reference diameter, lesion length and minimum luminal diameter (MLD) were measured before and after angioplasty, and at the time of follow-up angiography.

The diameter of the normal segment proximal to the traced area in the parent vessel was used to determine the parent vessel diameter, and the side branch reference diameter was determined from the diameter of the traced segment in the normal segment distal to the lesion in the branch. Lesion length was defined as the distance from the proximal to the distal shoulder of the lesion. Angiographic success was defined as post-PCI percent diameter stenosis less than 20% with at least Thrombolysis in Myocardial Infarction (TIMI) flow 3 in both the parent vessel and side branch. Procedural success was defined as the achievement of angiographic success in the absence of any in hospital major adverse cardiac events (MACE), which include death, myocardial infarction (MI) or emergency percutaneous treatment or coronary artery bypass grafting (CABG). Emergency coronary bypass surgery was defined as bypass surgery involving immediate transfer of the patient from catheterization laboratory to the operating room or within 24 hours of the procedure.

Follow-up angiography was planned for all patients at six months or earlier, if there was a clinical indication.

Restenosis was defined as .50% diameter stenosis of the treated lesion.

Clinical follow-up was obtained around six months after treatment by direct patient interview.

Target lesion revascularization (TLR) was defined as any repeat percutaneous intervention to the target lesion (parent or side branch) or any coronary bypass graft to the treated vessel during follow-up.

Six-month total MACE was defined as death, MI or target lesion revascularization during the follow -up period, plus in-hospital MACE.

Statistical Analysis

Data are expressed as mean SD for continuous variables, as numbers with percentage for categorical variables. Continuous data were compared using unpaired Student t test, and frequencies were compared using the chi-square or Fisher's exact test. A p value of 0.05 was considered statistically significant.

Results

Between group A and group B, there was no difference in baseline clinical characteristics except for the extent of coronary artery disease or the location of bifurcation lesion; more patients with one vessel disease were included in group A and more patients with two vessel disease were included in group B. (See Table 1 Baseline Characteristics - next page)

Baseline angiography characteristics of the parent vessel were similar in both groups. For side branch the vessel size and lesion length were greater in group B than Group A(3.5+_0.5 vs 2.0+_0.5 ,p 0.140 ; 20.0+_10.0 vs 10.0 +_0.5 p 0.001). (See Table 2)

In group B, the modified T technique and crush technique was used in the majority of patients. The procedure for Group B needed more stents (2-3) and longer time than Group A (60+_15 vs, 45+_15, p=0.001). The total stent length per patient was longer in Group B than Group A (38+_15 vs.38+_10,p=1). The final balloon/vessel ratio was similar in the two groups. Higher inflation pressure was applied in group B than in group A for both the parent vessel and the side branch (16+_4 vs.13+_3 p=0.07: 10+_4 vs.8+_4 p=0.07). All procedures were completed with simultaneous kissing balloon inflation in group A and B.

The angiographic follow-up rate for group A and group B were only done for those who were symptomatic (2 of group A and 3 of group B) and where there was found lesions in other arteries not the target artery that stented.

Follow-up QCA measurements of the parent vessel were larger in group B (3.5+_0.5 vs.3.0+_0.5 p=0.573). Patients of group B had side branches with a larger reference vessel size compared with patients of group A (2.5+_o.5 vs.2.0+_0.5 p=0.573). There was no difference between the two groups in the MLD. The angiographic restenosis rate was (0%) for patients in group B and (0%) for those in Group A. Clinical follow-up was accomplished in all patients.

The TLR rate was similar in the two groups (0%). Six-month total MACE, including TLR was similar in the two groups.

Table 1: Baseline clinical characteristics

Variables	Group A (70) N (%)	Group B (22) N (%)	P value
Hypertension			
Yes	30 (42.8)	15 (68.1)	0.06
No	40 (57.2)	7 (31.9)	
Diabetes			
Yes	5 (7.1)	5 (22.8)	0.09
No	65 (92.9)	17 (77.2)	
Hypercholesterolemia			
Yes	33 (47.1)	5 (22.8)	0.075
No	37 (52.9)	17 (77.2)	
Smoker			
Yes	28 (40)	18 (81.9)	0.001
No	42 (60)	4 (18.1)	
Family history			
Yes	24 (34.2)	5 (22.8)	0.45
No	46 (65.8)	17 (77.2)	
Prior MI			
Yes	29 (41.4)	18 (81.9)	0.002
No	41 (58.6)	4 (18.1)	
Previous angioplasty			
Yes	2 (2.8)	5 (22.8)	0.009
No	68 (97.2)	17 (77.2)	
One vessel			
Yes	35 (50)	2 (9.1)	0.001
No	35 (50)	20 (90.9)	
Two vessels			
Yes	20 (28.5)	8 (36.4)	0.67
No	50 (71.5)	14 (63.6)	
Three vessels			
Yes	15 (21.4)	12 (54.6)	0.006
No	55 (78.6)	10 (45.4)	
LAD diagonal			
Yes	10 (14.2)	4 (18.2)	0.92
No	60 (85.8)	18 (81.8)	
LCX / OM			
Yes	15 (21.4)	6 (27.3)	0.77
No	55 (78.6)	16 (72.7)	
RCA / PDA			
Yes	45 (64.2)	12 (54.6)	0.57
No	25 (35.8)	10 (45.4)	

Mean ± Std. Deviation			
Variables	Group A (70) N (%)	Group B (22) N (%)	P value
Age	46±11	52±10	0.031
LVEF	48±10	45±10	0.329

Table 2: Baseline angiographic characteristics

Variables	Mean ± Std. Deviation Group A (70)	Group B (22)	P values
Parent vessel			
Reference vessel (mm)	3±**0.5**	3±**0.5**	1
MLD (mm)	1±**0.5**	1±**0.5**	1
%DS (%)	75±**5**	75±**5**	1
Lesion length (mm)	20±10	30±**15**	0.001
Side Branch			
Reference vessel (mm)	2.0±**0.5**	3.5±**0.5**	0.140
MLD (mm)	0.5±**0.3**	0.5±**0.3**	1
%DS (%)	75±**10**	70±**10**	0.008
Lesion length (mm)	10±**0.5**	20±**10**	0.001

Table 3: Procedural characteristics

Variables	Group B (22) N (%)	Group A (70) N (%)
Angiographic success (%)	100	100
Procedural success (%)	100	100
In-hospital MACE (%)	0	0
Death	0	0
MI	0	0
CABG	0	0

Table 4: Angiographic and clinical follow-up

Variables	Mean ± Std. Deviation		P values
	Group A (70)	Group B (22)	
No. of patients who underwent angiographic FU	2	3	0.146
Angiographic FU duration (mo)	12±**6**	12±**6**	1
Angiographic restenosis (%)	0	0	
Parent vessel MLD (%)	3.0±**0.5**	3.5±**0.5**	0.573
Side branch MLD (mm)	2.0±**0.5**	2.5±**0.5**	0.573
No. of patients who underwent clinical FU	70	22	
Clinical FU duration (mo)	12±**6**	12±**6**	1
Re-PCI	2	3	0.146
Six month total MACE	0	0	

Discussion

The optimal strategy for percutaneous treatment of bifurcation lesions is one of the most widely debated issues in interventional cardiology.

To date, available data suggest that, in clinical practice, single stent implantation, when feasible, is not inferior to double stenting techniques.

However, it is also well established that a remarkable proportion of treated lesions may require double stenting to obtain angiographic success.

The relevance of the involvement of atherosclerosis in bifurcation lesions is underlined by the existence of a number of attempts to categorize these lesions, including the Duke, the Sanborn, the Safian, the ICPS, and the Medina classifications. Among these, the Medina classification is considered the most simple and has recently been recognized in a consensus report by European experts as the gold standard for bifurcation evaluation.

The best classification, however, should not only provide a simple description of the anatomy but should also help in selecting the appropriate stent implantation strategy.

Taking these assumptions as a starting point, we used the Medina classification prospectively in a consecutive series of patients with bifurcation lesions undergoing PCI in order to assign them to a single or double stenting strategy.

In our study, the angiographic results obtained in MV and SB with a single stent in group A did not differ from that obtained with 2 stents in the group B patients. Similar results have been obtained in other studies (7,8,9,10,11,18) in which double stenting of bifurcation lesions is not advantageous and seems also to have a detrimental impact on major clinical outcomes.

On the other hand, the selection of double stenting techniques in patients with the more complex Medina 1,1,1 lesions resulted in a high rate of angiographic success and warranted, over the long term, a clinical outcome that was comparable to that observed in patients with less complex bifurcations treated with single stenting.

The selection of Medina 1,1,1 further restricted the number of patients considered for double stenting in the present study compared to the classical definition of "true bifurcation" which also comprises Medina 1,0,1 and Medina 0,1,1 lesions.

The latter lesions were successfully managed with a single stent in the present study. Moreover, some patients with Medina 1,1,1 lesions may be treated by single stenting due to the presence of a SB anatomy that is not ideal for a second stent implantation (diffuse disease with absence of an appropriate stent landing zone, distal SB occlusion, presence of further division of the SB in multiple distal branches, etc).

Observational studies (8,9,10) have shown that up to 90% of jailed side branches are usually clinically silent and probably do not affect long-term clinical event-free survival and this may explain why most of the patients are asymptomatic even with jailed SB.

All together, these observations support the concept that only a minority of bifurcation lesions should be considered for double stent implantation techniques.

Finally, as previously shown by other studies (9,10) DES implantation seems to be necessary to treat bifurcation lesions as it is associated with a lower TLR rate and is an independent predictor of better clinical outcome as compared to BMS.

Study Limitations

1- In this study, we have arbitrarily hypothesized that the use of double stenting techniques may be reserved to treat Medina 1,1,1 lesions. This assumption has not been previously well established and remains controversial.

2- The failure to use dedicated software for the quantitative analysis of bifurcation lesions and the lack of systematic angiographic follow-up represent important limitations in the comparison of the acute angiographic results and the long-term outcome.

Conclusions

1- The selection of a single stenting strategy based on the absence of Medina 1,1,1 lesions is associated with a high rate of optimal angiographic results and with a low rate of bailout SB stenting.

2- The selection of a double stenting strategy only in patients with Medina 1,1,1 lesions is associated with a high rate of optimal angiographic results.

3- Both stenting strategies selected on the basis of the Medina classification are associated with a low rate of MACE.

4- In the absence of randomized trials, our observational study might help in the selection of a personalized stenting strategy for bifurcation lesions.

lesions involving bifurcation branches with diameter almost as big as that of the main branch or jeopardization of the side branch with TIMI flow less than three.

Recommendations

1- For treatment of bifurcation lesions a complex strategy of stenting both vessels provides no advantage in terms of procedural success and late outcome versus simple strategy of stenting only the parent vessel.

2- Double stenting of both main vessel and the side branch vessel in bifurcation lesion could be considered in cases of very big bifurcation branch, such as main stem lesions or lesions involving bifurcation branches with diameter almost as big as that of the main branch or jeopardization of the side branch with TIMI flow less than three.

Abbreviations and Acronyms

CABG = Coronary artery bypass graft surgery

DCA = Directional coronary atherectomy

MACE = Major adverse cardiac events.

MI = Myocardial infarction

MLD = Minimum luminal diameter

QCA = Quantitative coronary angiography

TIMI = Thrombolysis in myocardial infarction

TLR = Target lesion revascularization

LMS = Left main stem.

LAD = Left anterior descending artery.

LCX. = Left circumflex artery.

RCA = Right coronary artery

PDA = Posterior descending artery.

D1 = First Diagonal.

OM = Obtuse marginal.

DS% = Percent diameter stenosis.

LVEF = Left ventricular ejection fraction.

SD = Standard deviation.

FU = Follow up.

PCI = Percutaneous coronary intervention.

SB = Side branch.

MV = Main vessel.

References

1- Daniel Todaro, Francesco Burzotta, Carlo Trani, et al. Evaluation of a Strategy for Treating Bifurcated Lesions by Single or Double Stenting Based on the Medina Classification, Rev Esp Cardiol,2009;62(6):606- 14.

2- Gregory A. Sgueglia, Bernard Chevalier, Latina, Italy; and Massy, France Kissing Balloon Inflation in Percutaneous Coronary Interventions J A C C : C A R D I O V A S C U L A R I N T E R V E N T I O N S V O L . 5 , N O . 8 , 2 0 1 2.

3- Georgios Sianon; Marie-Angèle More; Arie Pieter Kappetein. The SYNTAX Score: an angiographic tool grading the complexity of coronary artery disease EuroInterv.2005;1:219-227

4- Gaku Nakawaza, Saami K, Y Zadani, Aloki V Finn. Pathological Findings at Bifurcational lesions, jack journals, April 2010. volume 55, Issue 16,

5- Nakawaz G, Yazdani SK, Vorpahi M, Kolodgie FD. Pathological Findings at Bifurcational lesions: The impact of flow distribution on atherosclerosis and arterial healing after stent implantation ,J Am Coll Cardiol 2010 april 20;55:1679-8

6- IOANNIS IAKOVOU, ANTONIO COLOMBO Centro Cuore Columbus and San Raffaele Hospital, Milan, Italy Two-Stent Techniques for the Treatment of Coronary Bifurcations with Drug-Eluting Stents Hell J Cardiol ,2005 ,46: 188-198,.

7- Jassim AL Suwaidi; Peter Berger, Chraranjit S Rihal ,Kirk N Garratt. Immediate and long term out come of intra coronary stent implantation for true bifurcational lesions. J Am Coll Cardiol ,2000;35 (4); 929-936.doi;10.1016/S0735-1097(99)00648-8.

8- Katritsis DG, Siontis GC, Ioannidis JP et al. Double versus single stenting for coronary bifurcation lesions: a meta analysis, circinterventions, ahajournals.org by guest on april 25,2013-

9- Takehiro Yamashita, Takahiro Nishida, Milena G. Adamian, , Carlo Briguori, Marco Vaghetti, Nicola Corvaja, Remo Bifurcation Lesions: Two Stents Versus One Stent Immediate and Follow-up Results Journal of the American College of Cardiology, 20005 Vol. 35, No.

10- Takehiro Yamashita, Nicola Corvaja Remo Albero. Bifurcational lesions: Two stent versus one stent - immediate and follow up results, J Am Coll Cardiol ;2000;35(5); 1145 1151,dio;10,1016/S0735-1097.

11- Keiichi Tsuchida, Antonio Colombo, Theirrey Lefevere. The clinical outcome of percutaneous treatment of bifurcation lesions; European Heart Journal (2007)28 ,433-442.

12- Erik Jorgensen and Steffen Heiqvist. Stent treatment of coronary artery bifurcation lesions; European Heart Journal;(2007)28,383-385.

13- Ioannis Iakovou. Contemporary Stent Treatment of Coronary Bifurcations HOSPITAL CHRONICLES 2006, SUPPLEMENT: 110-114.

14- Azeem Latib and Antonio Colombo. Management of bifurcational lesions; Interventional cardiology unit Ssn Raffaele Scientific Institute, Milano, Italy, Via Buonarroti 2004, 48, 20145.

15- Angela Hoye,Ionnis Lakovou; Lei Ge,. Long term outcomes after stenting bifurcation lesions with Crush Technique; Jacc Journal, May 2006 Volume 47,Issue 10.

16- Yves Louvard, Martyn Thomas, Vladimir Dzavik. Classification of coronary bifurcation lesions and treatment; catheterization and cardiovascular interventions (2008) 71; 175-183.

17- Aron V. Kaplan. Percutaneous coronary intervention Treatment of bifurcation lesions; J Am Coll Cardiol 2009;195-196,doi;jcin 2009.01.003.

18- Andrejs Erglis; Indulis Kaumsars; Matti Niemela ; Randomised comparison of coronary stenting with crush versus the culotte technique using sirolimus eluting stent; Cardiovascular intervention ,2009;2;27-34.

19- Keiichi T Suchida, Antonio Colombo, Thierry Lefever. Stent treatment of coronary artery bifurcation lesions; European Heart Journal (2007)doi;10.1093.

20- Y.Louvard. ICPS, Massy, France; One stent or two stents in coronary bifurcations: Athappan, J Cardiovascular med 2010,11:103-110.