# It must be true: Accept your colour, stop hunting for skin whitening, black is beautiful

**Ebtisam Elghblawi**

**Correspondence:**
Dr Ebtisam Elghblawi
MBBCh, MScRes, ADD, DRH.
Private Practice
P.O.BOX 3232
Tripoli
Libya
**Email:** ebtisamya@yahoo.com

## ABSTRACT

**Skin is the most voluminous structure of the body. It not only presupposes a physiological duty but embodies a 'social interface' among the individual and others. It occurs to be standing the most researchable constitution in the cosmetic business. Generally speaking there is an exponential interest both from the doctors as well as our patients seeking resolutions towards maintaining and attaining a perfect skin.**

**White skin is the dream of all Arab women with a particular attention in Libya and a fair skin is symbolized as a beauty sign. Libyan women tend in the summer time to shade themselves from the sun and deprive themselves from the benefit of sun and vitamin D for their big wedding day. Skin lightening cosmetics are widely used in most African countries including Libya where Libyan women are obsessed by it due to certain brands ruthlessly advertising fair and lovely skin, and it is a growing problem.**

**Use of cosmetic products to bleach or improve the skin texture and colour is a habit chiefly among dark-skinned Libyan women.**

**The concept of having white' skin complexion has been considered trendy and desirable.**

**The active ingredients in these cosmetic products are mainly hydroquinone, mercury and corticosteroids in higher concentrations. Several additives are used to enhance the bleaching achievement.**

**Since these products are used mostly for longer periods, on a large body surface area, and under hot moist circumstances, the per-cutaneous absorption is boosted. Thus the complications of these products are very detrimental and sometimes can be deadly (Table 2).**

**In many instance ladies who buy those products without any medical consultations or prescriptions will only present to professionals when drawbacks are incurred. Such patients have tried everything, both at home and also in other clinics - and on occasion spending what amounts to a fortune on products and treatments that have little or no effect at all.**

**Hyperpigmentation disorders and skin lightening treatments have a significant impact on the dermatologic, physiologic, psychological, economic, social, and cultural aspects of life. Raising patient's awareness is vital to avoid such irreversible complications.**

**To come to a close and sum up, it is mandatory to raise more knowledge and understanding on the occurrence and dangers of this misuse practice.**

**Key words: steroids, hydroquinone, depigmenting agents, skin bleaching, cosmetics.**

## Aim of this paper

The use of skin bleaching products for cosmetic purposes is a very popular practice in dark skinned women from Libya. The dermatologic complications associated with this practice have been comprehensively reported in the existing literature. The aims of this review paper is:

**1-** to shed light on the potential aspects of their complications in the long run and to
**2-** enlighten about the clinical practice and the proper advice to be given to patients who seek such medications
**3-** to increase the knowledge about the dermatological consequences of this practice in the Libyan community.

## Introduction

Skin lightening (bleaching) cosmetics and toiletries are extensively applied in most African countries including by Libyan women in Libya (Figures 1-3). In fact, the use of cosmetic products to bleach or improve the skin texture and colour is an ordinary habit among dark-skinned Libyan women.

The usual active ingredients in these cosmetic products are mainly hydroquinone (strong oxidant), mercury and corticosteroids in higher concentrations (Figures 1 & 4 & 7 & 8). Some are unknown (Figure 11). Several additives are added to augment the bleaching effect. Hydroquinone is a melanocyte toxic product which combats melanogenesis (Table 1).

Since these products are used usually for long duration, with various concentrations, on a large body surface area, and under hot humid conditions, thus the per-cutaneous absorption is enhanced and subsequently complications occur (Dadzie& Petit 2009).

The history of practicing skin bleaching dates back over many years in diverse communities around the globe. In reality, in the early era around 1900s some American physicians proposed utilization of radiation as a skin bleaching agent (Dadzie & Petit 2009).

The complications of these products are very detrimental and sometimes can be deadly (Table 1). Some of the well known complications are allergic contact dermatitis, Steroid induced monomorphic acne (Mahé et al 2003, Nnoruka and Okoye O 2006, Poli 2007), exogenous ochronosis (Figure 1) (Gandhi et al 2012, Kombaté et al, 2012), skin thinning (papering) (figure 5&6&9&10), dyschromia (Mahé et al 2003) and hypo/hyper chromia (leucoderma) and prominent striae atrophy (Nnoruka and Okoye O 2006), bruise, echymosis, telangiectasias (figure 6), impaired wound healing, wound dehiscence, with inclination to infections, candidiasis and mycosis (Mahé et al 2003, Nnoruka and Okoye O 2006), tinea corporis, pyoderma, cellulitis, peri-oral dermatitis (Mahé et al 2003), erysipelas, facial hypertrichosis and macular hyperpigmentation of face/ macular hyperchromia (Nnoruka and Okoye O 2006), and some claimed scabies (Mahé et al 2003) and warts, mercurial nephropathy, peripheral neuropathy (Mahé and Perret 2005), cataracts, glaucoma, eye infections and blindness, steroid addiction syndrome, immunosuppression, lichenification, scarring, poilkiloderma, brown nails, elastosis, roseacea, leucomelanoderma, vibices, burn, sun burn, eczema, Diabetes mellitus (Nnoruka and Okoye O 2006), nephrotic syndrome (Tang et al 2013), and a broad spectrum of cutaneous and endocrinologic complications of corticosteroids, including suppression of hypothalamic-pituitary-adrenal axis resulting in systemic complications such as hypertension, hypercorticism (Pitché et al 2005, Dadzie& Petit 2009).

In that essence, there has been a report in the Medical Observer of Australia about a hypoadrenalism in a 24-year-old Sudanese woman who was referred for investigation of fertility problems and found to have low serum cortisol (Rouse 2015). Her GP noted she had a darker skin complexion; however her face was a lighter shade. On questioning her she revealed the use of two over-the-counter creams bought at a suburban store selling African commodities; those creams were fluocinonide 0.075% and hydrocortisone acetate 1% and were used for many years (Rouse 2015). The explanation of the suppression of the hypothalamic-pituitary-adrenal axis is simply the per cutaneous steroids systemic absorption. And in the existing literature, this has been confirmed (Perret et al 2001). Moreover cases of nephrotic syndrome have been reported in relation to the use of bleaching agents where the main culprit was mercury and such patients should be sent for assessing the blood and urine level of protein and mercury (Tang et al 2013).

The exogenous ochronosis is reported to occur with higher concentration of 8% and can be seen within 5 years of continuous application of hydroquinone products (Ly&Soko et al 2007). However Gandhi et al 2012 reported its occurrence with only 2% concentrations.

Moreover hydroquinone which is composed of benzene derivate is well known to be with carcinogenic properties and teratogencity in vivo. Some few studies documented the associations between developments of cutaneous malignancy in relation to hydroquinone (type 2). This has been claimed to be postulated to be through its pro-carcinogenic effect or due to suppression of the natural photo-protection effect of melanin, however it is still a contradiction to prove and needs further studies to confirm (Dadzie & Petit 2009). Hydroquinone is well known with a photosensitizing effect in different concentrations, and has been hugely marketed for 50 years as a skin-lightening product and continues as the most customarily used whitening constituent in the assembly (Mahé & Perret 2005).

In the old days, hydroquinone and other cutaneous depigmenting products were broadly prescribed by dermatologists to combat pigmentary disorders, and in many instances it carries a variety of side-effects, including mercury poisoning. (Dadzie & Petit 2009).

Issues and apprehensions have been elevated regarding its impending dermatological and systematic side effects, which led to ban all hydroquinone products from the US market by the FDA on 29 August 2006 (Dadzie & Petit 2009). This has led the dermatology community to publish some papers in regard of this ban and address the FDA concerns and the risks around hydroquinone. However in the third world, including Libya, it is still considered, prescribed and used as a lightening agent.

Wood's lamp can be a helpful tool to assess the level of the hyperpigmentation.

**Table 1: different bleaching agents and mode of action and side effects**

| Agent-active ingredients | Mode of actions | Side effects |
|---|---|---|
| **Hydroquinone**<br>1,4-dihydroxybenzene | strong oxidant<br>melanocyte toxic.<br>inhibitor of melanogenesis | Irritant and allergic contact dermatitis, with following post-inflammatory dyspigmentation, peripheral neuropathy, exogenous ochronosis<br>Nail plate pigmentation |
| **Corticosteroids**<br><br>clobetasol-containing agents | initial local vasoconstriction occurring when applied to the skin, giving an impression of an immediate reduction in pigmentation of the skin<br>Inhibitory effect on epidermic melanogenesis. | > 3 weeks, especially on thin skin i.e facial and flexural, is associated; Striae, peri-oral dermatitis, rosacea-like eruption, acne vulgaris, telangiectasia, poor wound healing, easy bruising and hypertrichosis. Other side-effects; ophthalmic i.e (cataracts, glaucoma, eye infections & blindness) associated with the application of topical steroids to the face, especially the eyelids and aseptic osteonecrosis (personal observations). Cutaneous infections such as dermatophytosis, cellulitis, erysipelas, scabies and warts, |
| **Mercury** (salts)<br><br>Currently skin lightening is also a cause of mercury toxicity (Hatters disease). | inhibition of melanin formation | Hatters disease= psychiatric (disturbance of recent memory, impairment of intellectual function, inattention and depression) and neurological (irritability, memory loss and neuropathies) problems renal impairment (minimal change or membranous glomerulonephritis), paradoxical increase in skin pigmentation, due to direct deposition of metallic mercury granules in the dermis |
| Kojic acid (KA)<br><br>and<br><br>glycolic acids (GA) | KA is tyrosinase Inhibitor and an antioxidant. derived from various fungal- Aspergillus and Penicillium.<br><br>GA is alpha-hydroxyl acids derived from sugar cane- At low concentrations; it has an epidermal discohesive effect, while at high concentrations it results in epidermolysis.<br>Both lead to removal of the superficial epidermis thus a depigmenting effect when used for skin lightening.<br>Additional possible depigmentation include rushing of keratinocytic turnover with a drop in their melanosome loading time. | Irritant contact dermatitis, with the risk of post- inflammatory hyperpigmentation (PIH). |

**Table 2: Briefing of Aesthetic complications**

| | |
|---|---|
| Trophic issues | Striae, skin atrophy and scaring |
| Pigmentatory issues | Darkening, leucoderma, periorbital hyperpigmentation (spectactes), exogenous onchronosis, polikoderma, variegate appearance |
| Lichenoid issues | lichenfication |
| Vascular issues | Telangectasia and lilac redness of eyelids, bruise |
| Exoskeleton | Facial hirsutism and brown nails |
| Joints | dyschromia, including hyperpigmentation of the joints |
| Others | peritibial ichthysois, purpura, Pigmented keratosis pilaris, erythrosis of the elbow |

**Figure 1: Ochronosis**

**Figure 2: Uneven complexion and requested for lightening products**

**Figure 3: Post strong steroids cream**

**Figure 4: Hyperpigmentation from different treatment she used including strong steroids**

**Figure 5: Uneven colour with dark knuckle due to strong steroids application for 4 years**

**Figure 6: Thin skin and telangectasia due to steroids**

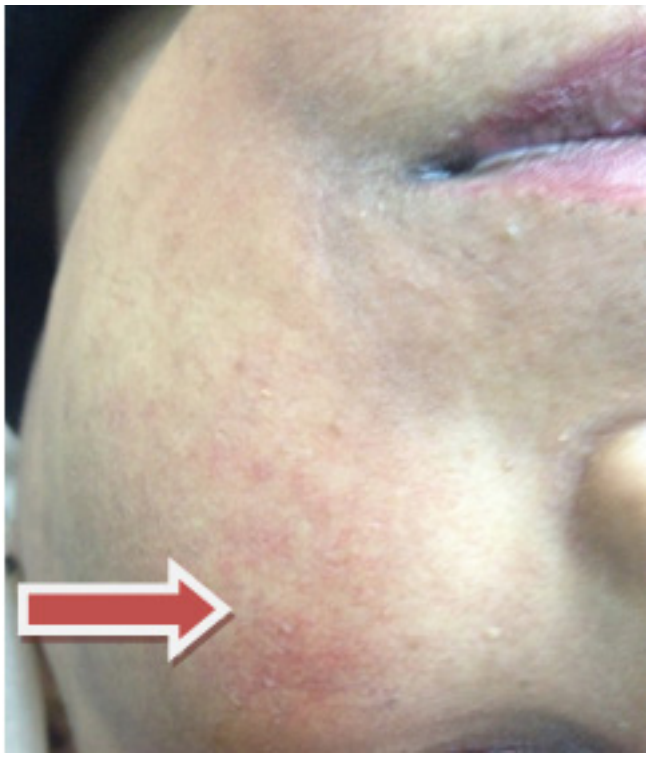

**Figure 7: Black ladies favour this cream for whitening - clo-betasol**


**Figure 8: Patients are taken by the title WHITE CREAM**

**Figures 9 and 10: Post 4 years gamavate cream**

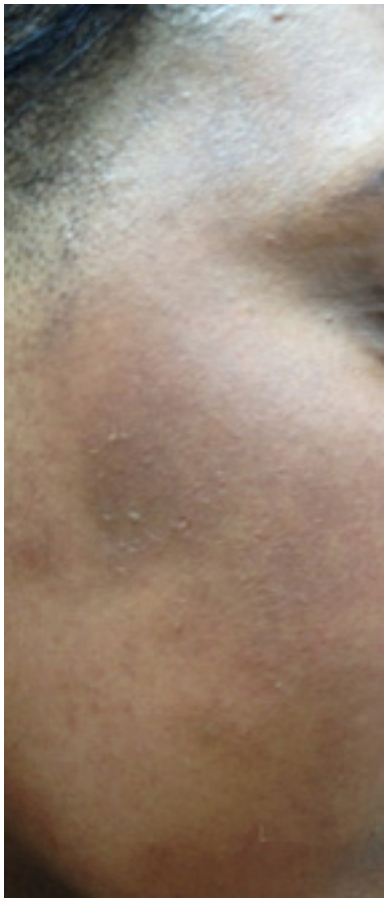

**Figure 9**

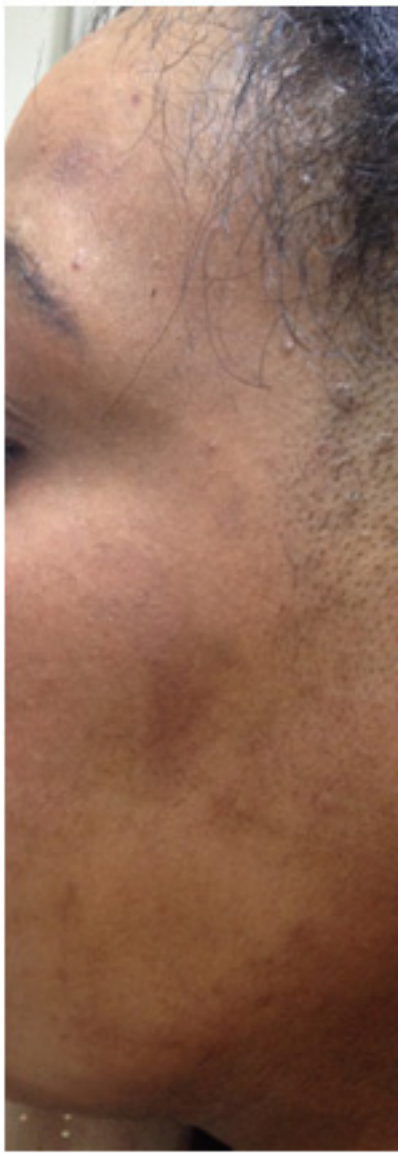

**Figure 10**

**Figure 11: A cream without ingredients listed**

## Libyan Traditional Ways to Lighten up their Skin

The cultural practice of skin bleaching to lighten normally dark skin (mostly Fitzpatrick skin photo-types IV to VI) is highly prevailing in Libya. The most common traditional modalities of the skin bleaching practice in Libya are: lemon, saffron and turmeric.

Some have gone far and do use different food herbs and spices such as 2 TSF saffron or turmeric powder with 1 TSF honey, 1 TSF rose water, 1 TSF cornstarch and then mixing them up with 1TSF fresh lemon juice all of which is mixed and applied on face for one hour until it has dried up and then remove as a scrub to lighten up their skins. Another mix is pea's powder mixed with lemon juice in gauze and applied as a mask on the face. Another way is a cane milk mixed with fresh lemon juice. Also for the body, they mix henna powder with water and leave on the body with rose water. Also others would mix peas with honey and rose water and leave as a mask then peel off. Also mixing Tafal (green material paste) or Barouuk (it's a white stones form to grind into a white powder, and to be mixed with rose water and applied on the face and it is called an instant bridal whiting complexion and well known in Tunisia) which is mixed with rose water and left on the face until dried up to give the whitish complexion of the face, also dried yeast granules mixed with water and left to ferment and then add rose water, as well as Felyia and cucumber water mix. Also in the old days they grind cinnamon in the mouth and then apply on the cheeks to give the red tint.

Libyan women did not stop at this level; however some sought the use of some creams by their peers, to attain the whitish complexion, as some go beyond on to using local strong steroids namely Gamavate and Decloban creams (clo-betasol, and fluocinonide) from OTC and I met some who think and strongly believe they are the beauty creams. The most common places where Libyan women tend to apply such agents on, is face, neck, dorsa of the hands, elbows, between thighs and knees in order. And the duration of the practice varied from 1 month to few years as most declared. Women tend to buy them without any medical prescription.

The high use of super potent steroids is reported to be alarming and striking (Mahé et al 2003). Libyan women find strong steroids application to be appealing as they are potent lighteners for their skin tone and complexion, and the most observed bleaching products among black women were the blind application of super-potent topical steroids class I which appeared to be the main culprits responsible for the observed skin complications in the clinical setting.

This fact is attributed to the easily accessibility to strong steroids which in many instances are free of charge at polyclinics in Libya and if not, they are available at low prices at private pharmacies.

From my observation, it seems the most concerning skin diseases motivating ladies visits to the dermatology clinic are complications of that misuse practice, i.e. pigmentation disorders or caustic effects of their own choices of applications (Mahé et al 2003).

In some cases the dermatological diagnoses were based mainly on clinical grounds; this reflects that the dermatological, where clinical accuracy or the diagnosis of common dermatoses appears good and perceived (Mahé et al 2003).

Also in many places where the products claimed to be a "natural" skin bleacher, was found to be containing higher concentration of hydroquinone or corticosteroids, or even both simultaneously (Mahé& Perret 2005). I recall in the old days, ladies were obsessed by Shirley cream and fair and lovely cream to have a lighter skin.

## Discussion

Topical strong steroids have surfaced in the latest years as chief facial skin lighteners, due to their potent bleaching power, and perhaps also their anti-inflammatory activity that could limit the risks for dermatitis; nevertheless, they appeared here as the main cause to blame for the complications observed with ladies (Mahé et al 2003)

Nowadays in the last few years, the new trend is for promoting and advertising glutathione and others as antioxidants without any harmful agents, in the form of tablets and injections in different strengths, and they are marketed strongly without any proper monitoring, studies, inspection and legislations and patients are deceived by the description of it is magical results attained in a few months and in most cases patients are zealous and taking by such attractive commercials products and are willing to pay a fortune to achieve the ultimate wishes and yearning desire for a fair supple skin. This is because the white and pale skin is considered as a beauty sign and social privileges for better groom proposal and working chances. In Libya in many places, dark and black skin is still considered as a negative cultural perception and stigma. Moreover some far east people who have olive skin, and who are more working in the nurse field in Libya, such as Philipinos tends to use such products more as well to attain the white radiant skin. This phenomenon is sweeping Europe the other way around, where western women go to the tanning salon to acquire the dark glow.

There are many various wide varieties of different skin-lightening brands in the Libyan market which are being imported from overseas, and bearing the fact of the high demand to purchase such products for such skin- lightening products in this country make it a flourishing business.

The total sales volume of skin lighteners is high in Libya and there is no rough estimation due to the lack of registrations and records.

The most common excuses for such products encountered in the clinical settings are: to improve the skin before marriage, to get rid of blemishes on the face and other parts of the body, to attain a beautiful radiant skin, to even out the skin tone and some as a fashionable trend heard by their peers.

Also in the clinical setting I in many instances encountered a request for skin bleaching treatment by some patients to lighten up their complexion.

There is not any evidence based clinical trials yet on their safety, method of actions, nor the long run complications and consequences. Its temporary effects and need to be continuous as some medical colleagues declared from their patient's outcome, plus it is a means for a very lucrative business for many marketing companies.

Patient awareness of their risks is vital and thus it is critical for every practicing physician to be aware of these complications and raise awareness for those ladies who turn up in the clinic asking for them officially.

Skin lightening compounds, such as hydroquinone and topical corticosteroids, are often prescribed and used to treat hyper-pigmentation disorders; namely melasma, or lighten skin for cosmetic purposes. In spite of their recognized usefulness, huge dermatological and systematic complications have been linked with them. Authorized bodies have identified the drawbacks of skin lighteners and questioned the safety of this substance, and in fact it is nowadays forbidden in certain countries to sell such products. This has led to the possibility of exploring other alternatives to inhibit skin pigmentation such as retinoids, azelaic acid, arbutin, kojic acid, aleosin, mequinol, licorice extract, ascorbic acid, soy proteins, and N-acetyl glucosamine.

Dermatologists and users of such products should be attentive of the various components in bleaching compounds, and their potential impediments.

The management of the aesthetic complications of artificial skin whitening causes real problems, and the therapeutic means available are financially inaccessible to most patients living in developing countries. Trophic disorders, whether skin atrophy or striae atrophicae, are beyond any therapeutic resources.

The general state of welcoming bleaching and whiting in the Libyan community could arise from the inherent feeling of having a fair skin in the community which signifies beauty and attraction to the counterpart gender.

## Conclusion

This article hints to a number of traditional bleaching methods that have a certain beauty and mystery for Libyan women's culture. This personal observation of high demand and use of super potent steroids is striking, as in fact most of such products are easily accessible through pharmacies without a prescription. The motivations of such patients to visit a doctor are the complications incurred of such practice.

The misuse of over-the-counter (OTC) cosmetic and bleaching agents must be banned and forbidden and there should be some legislation incurred on pharmacies onto not selling such products without a prescription, and emphasizing consulting a dermatologist beforehand. Usually patients in Libya attain such topical products by unregulated bodies including pharmacies.

Such patients usually presented particularly complex medical, social and emotional problems, where they are desperate for a solution and willing to pay anything.

Moreover in the dermatology communities, a discussion on the safety of bleaching agents including hydroquinone should offer a sole occasion to raise consciousness and understanding about skin bleaching risks and mandate careful consideration and selection.

Now with the introduction of the internet, some people's access to unscrupulous suppliers via the internet to avoid costs of professional consultation, and most of Libyan women have an access especially to the social media, like facebook where many marketers use it to promote their business solo and informally without any regulation and legislation; they just post and ask the client privately about the price and the delivery mode. Such marketing places an effective tempting post, where most women are taken in by and cannot resist, and especially single ones and they buy them without any prior consultation to attain that fairer skin for the big wedding day that she ever dreamt and wished for.

Self administration is dangerous and fraught, not least due to no safe information about the products name, exact formulations and safety, neither provided nor approved by the regulatory bodies.

The purchase of medications over the internet is utterly poorly unregulated and this poses an even greater problem that should be tackled and addressed. Moreover, Libyan women can easily obtain topical strong strength corticosteroids without any medical prescription.

Each case reported should be taken seriously and should be reviewed thoroughly and analyzed.

The breakdown by level of education and application was not explored among women but most of them state their peers applied it and advised about it.

Aesthetic complications associated with artificial bleaching and depigmentating products are common, but are rarely the reason for consulting a dermatologist. In the absence of suitable therapeutic agents, prevention, based on informing women of the damaging effects of artificial depigmentation, is the only way forward.

We need to educate ladies and men's with pigmentory problems to request early dermatological consultation for their dermatoses, rather than to self- medicate with over-the-counter or illegally obtained cutaneous depigmenting bleaches to avoid complications which would impact the patients at the sociological and psychological levels.

There is a need for appropriate public health prevention campaigns to raise awareness to combat such illegal trafficking of bleaching agents to implement.

There is a need for rigorous scientific studies, especially in the Arab world where such studies remain scarce, to critically evaluate the global burden and adverse health effects associated with skin bleaching.

In many instances, the aesthetic complications of artificial skin bleaching causes real problems and beyond any financial affordability, and any possible corrections and less than optimal, such striae atrophicae, skin atrophy, and exogenous ochronosis. Some claimed that Nd:Yag 1064-nm laser system is a bit effective in ochronosis.

There should be a form of protection, such as photoprotection, should be the rule. Any product to be used of those bleaching products must comply with the legislation in force.

The take home message and the general rule for such patients is to keep away from direct sun lights, as both UVA and UVB rays are responsible and both likewise accountable for deepening pigmentation. For instance, UVA rays penetrate deeper into the skin than UVB rays, and cause wrinkles and age spots. Thus in that instance "A" for ageing. While UVB rays are responsible for tanning. Thus "B" for burning. In order to combat pigmentation and prevent further damage and protect the skin, a sunscreen with a minimum protection of SPF30 is mandatory and essential. Also it is vital to increase awareness of the potential complication of cumulative body glucocorticoid excess syndromes and the consequences for secondary adrenal insufficiency are important to minimise problems.

## References

Gandhi V, Verma P, Naik G. Exogenous ochronosis After Prolonged Use of Topical Hydroquinone (2%) in a 50-Year-Old Indian Female. Indian Journal of Dermatology. 2012;57(5):394-395.

Pitché P; Kombaté K; Tchangai-Walla K, International Journal Of Dermatology [Int J Dermatol], ISSN: 0011-9059, 2005 Oct; Vol. 44 Suppl 1, pp. 39-40

Dadzie, O. E., & Petit, A. (2009). Skin bleaching: highlighting the misuse of cutaneous depigmenting agents. Journal Of The European Academy Of Dermatology And Venereology: JEADV, 23(7), 741-750

Ly F, Soko A, Ndiaye B, et al. Aesthetic problems associated with the cosmetic use of bleaching products. International Journal Of Dermatology [serial online]. October 2007;46 Suppl 1:15-17

Mahé A, Ly F, Aymard G, Dangou J. Skin diseases associated with the cosmetic use of bleaching products in women from Dakar, Senegal. The British Journal of Dermatology [serial online]. March 2003; 148 (3):493-500

Mahé A; Ly F; Perret JL. Systemic complications of the cosmetic use of skin-bleaching products. International Journal of Dermatology [Int J Dermatol], ISSN: 0011-9059, 2005 Oct; Vol. 44 Suppl 1, pp. 37-8

Kombaté K; Mouhari-Toure A; Saka B; Akakpo AS; Maboudou A; Pitché P; Tchangaï-Walla K. Acne and skin bleaching in Lomé, Togo. International Journal of Dermatology [Int J Dermatol], ISSN: 1365-4632, 2012 Nov; Vol. 51 Suppl 1, pp. 27-9

Poli F. Acne on pigmented skin. International Journal of Dermatology [Int J Dermatol], ISSN: 0011-9059, 2007 Oct; Vol. 46 Suppl 1, pp. 39-41

Rada Rouse. 2015. An unusual reaction to skin-lightening cream. Medical observer. http://www.medicalobserver.com.au/medical-news/an-unusual-reaction-to-skin-lightening-cream

Perret JL, Sane M, Gning S, Ba K, Rohou G. [Hypothalamo-hypophyseal-adrenal hypofunction caused by the use of bleaching cosmetics in Senegal]. Bull Soc Pathol Exot. 2001;94(3):249-52

Nnoruka E, Okoye O. Topical steroid abuse: its use as a depigmenting agent. J Natl Med Assoc. 2006; 98 (6):934-9

Tang HL, Mak YF, Chu KH, Lee W, Fung SK, Chan TY, Tong KL. Minimal change disease caused by exposure to mercury-containing skin lightening cream: a report of 4 cases. Clin Nephrol. 2013; 79 (4):326-9.